



## Ultra-high field imaging of the amygdala – A narrative review

Cedric Fabian Kirstein<sup>a,\*</sup>, Onur Güntürkün<sup>a,b</sup>, Sebastian Ocklenburg<sup>a,c,d</sup>

<sup>a</sup> Department of Biopsychology, Institute of Cognitive Neuroscience, Faculty of Psychology, Ruhr University Bochum, Germany

<sup>b</sup> Research Center One Health Ruhr, Research Alliance Ruhr, Ruhr-University Bochum, Bochum, Germany

<sup>c</sup> Department of Psychology, MSH Medical School Hamburg, Germany

<sup>d</sup> Institute for Cognitive and Affective Neuroscience, MSH Medical School Hamburg, Germany

### ARTICLE INFO

#### Keywords:

Amygdala  
Neuroimaging  
7T  
Ultra-high field imaging  
Fear processing  
Anxiety

### ABSTRACT

The amygdala is an evolutionarily conserved core structure in emotion processing and one of the key regions of interest in affective neuroscience. Results of neuroimaging studies focusing on the amygdala are, however, often heterogeneous since it is composed of functionally and neuroanatomically distinct subnuclei. Fortunately, ultra-high-field imaging offers several advances for amygdala research, most importantly more accurate representation of functional and structural properties of subnuclei and their connectivity. Most clinical studies using ultra-high-field imaging focused on major depression, suggesting either overall rightward amygdala atrophy or distinct bilateral patterns of subnuclear atrophy and hypertrophy. Other pathologies are only sparsely covered. Connectivity analyses identified widespread networks for learning and memory, stimulus processing, cognition, and social processes. They provide evidence for distinct roles of the central, basal, and basolateral nucleus, and the extended amygdala in fear and emotion processing. Amid largely sparse and ambiguous evidence, we propose theoretical and methodological considerations that will guide ultra-high-field imaging in comprehensive investigations to help disentangle the ambiguity of the amygdala's function, structure, connectivity, and clinical relevance.

### 1. Introduction

The amygdala is a subcortical structure located bilaterally in the medial temporal lobes. It plays a crucial role in processing emotional information, especially fear, and social stimuli (Güntürkün, 2019). The amygdala's importance for fear processing is evident in patients with the heritable Urbach-Wiethe's syndrome (Urbach and Wiethe, 1929). In this condition, following the calcification of intra-amygdalar blood vessels, patients are unable to recognize and express fear while other emotions remained relatively intact (Adolphs et al., 1994; Feinstein et al., 2011). Furthermore, affected patients have difficulties with appropriate assessment and behavior in social situations and decisions under risk or ambiguity (Adolphs et al., 1998; Brand et al., 2007).

The amygdala is relevant for several neurological and psychopathological disorders. Based on neuroimaging studies, it is assumed that the amygdala plays a role in major depression disorder (MDD; Rubinow et al., 2016). Structural and functional anomalies have also been found in bipolar affective disorder (Garrett and Chang, 2008), anxiety disorders (Rauch et al., 2003), schizophrenia (Aleman and Kahn, 2005),

epilepsy, and Alzheimer's disease (Benarroch, 2015). However, results on the amygdala's involvement in psychopathology are ambiguous. For instance, in a 2008 meta-analysis of 13 studies, Hamilton et al. found increased amygdala volumes in medicated patients and decreased amygdala volumes in non-medicated patients with MDD (Hamilton et al., 2008). In a review article, Besteher et al. (2020) identified 16 studies on brain structure and subclinical depression, of which only one found a relationship between amygdala structure and depression. However, they identified six studies that reported either positive or negative correlations between the whole amygdala volume and subclinical anxiety, only one of which attributed the activity to a specific subnucleus of the amygdala, i.e., the basal nucleus (Iidaka et al., 2006).

The core issue in neuropsychiatric amygdala research is that it is not a unified structure but is composed of at least 13 functionally and structurally distinct subnuclei (Pabba, 2013). Some researchers even distinguish between as many as 17 subnuclei in the rat amygdala (McDonald and Mott, 2017). The comprehensive cellular-resolution atlas by Ding et al. (2016) describes 15 subnuclei in the human amygdala (see Fig. 1). Table 1 shows the functions of each nucleus. Some of

\* Correspondence to: Abteilung Biopsychologie, Institut für Kognitive Neurowissenschaft, Fakultät für Psychologie, Ruhr-Universität Bochum, Universitätsstraße 150, 44780 Bochum, Germany.

E-mail address: [cedric.kirstein@rub.de](mailto:cedric.kirstein@rub.de) (C.F. Kirstein).

<https://doi.org/10.1016/j.neubiorev.2023.105245>

Received 30 January 2023; Received in revised form 11 May 2023; Accepted 21 May 2023

Available online 24 May 2023

0149-7634/© 2023 Elsevier Ltd. All rights reserved.

the subdivisions, like the intercalated amygdala or the amygdaloatrial transition area are not widely investigated in neuroimaging studies. Therefore, there is no published data available on the volume of these structures. Table 2 shows the volumes of the most prominently investigated nuclei.

These subnuclei are commonly summarized into two distinct groups: the basolateral and centromedial nuclei (LeDoux, 2007). Other authors suggest categorizing it into a lateral, basolateral, medial, and central nuclei complex (Janak and Tye, 2015). Previous research demonstrated that the nuclei and their substructures serve different purposes. The lateral nucleus, for example, has been shown to serve as the main input center for afferences from the thalamus and cortex and plays an important role in the integration of stimuli in fear conditioning (Güntürkün, 2019; LeDoux, 1993; LeDoux and Müller, 1997). Plasticity in the basolateral amygdala is thought to be involved in the implicit formation of the emotional component of memories during fear conditioning (Fanselow and Ledoux, 1999). The central nucleus is crucial in pain processing as it receives nociceptive input from the parabrachial nucleus (Allen et al., 2021) and sends efferent signals to the nucleus basalis Meynert in threatening situations (Güntürkün, 2019).

The present narrative review aims to provide an overview of the current state of ultra-high field imaging research of the amygdala to foster a more comprehensive understanding of amygdala function than can be achieved based on the heterogeneous results of imaging studies with lower magnetic field strengths. In scope of this review, we define ultra-high field imaging as functional magnetic resonance imaging using magnetic field strengths of 7 T or higher. As described above, the amygdala's subnuclei are differentially involved in diverse brain functions. Thus, after an introduction to ultra-high field imaging, we review the literature on amygdala functions. Since the subnuclear functional heterogeneity of the amygdala is inseparably linked to heterogeneity in connectivity, we then investigate the present literature on the structural and functional connectivity on the subnuclear level. After a description of these physiological foundations, we subsequently provide a synthesis of clinical ultra-high field amygdala studies.

## 2. Methods

Using PubMed, we conducted a literature search adopting the terms “7 Tesla” OR “ultra-high field” combined with the terms “amygdala” OR “amygdaloid”. We included studies that 1) used field strengths of 7 Tesla or higher, 2) examined the amygdala as the main or secondary region of interest, and 3) secondary literature on ultra-high field imaging including findings on the amygdala. Exclusion criteria comprised 1) lower field strengths than 7 T, 2) investigations solely of the BNST, 3) non-human studies, and 4) no available full-text articles.

A total of 30 studies met our search criteria. Of these, we found nine studies on the functional properties of the amygdala, twelve studies on

**Table 1**

Overview of previous findings on the functions of the amygdala subnuclei.

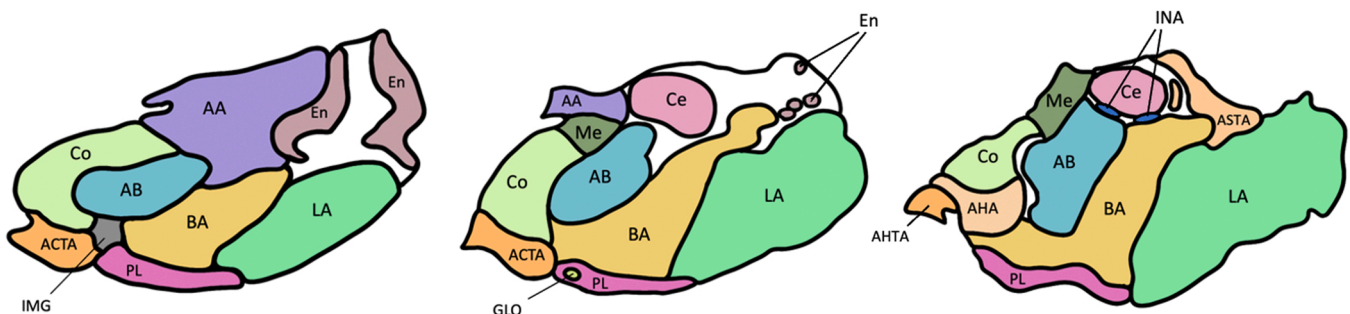
Nucleus	Function
Anterior amygdalar area	Configural conjunction of fearful eye and mouth movements (left; (Morris et al., 2002)
Accessory basal nucleus	Top-down control of anxiety and fear, fear extinction in mice (Adhikari et al., 2015)
Amygdalocortical transition area	Delivers hippocampal input of emotional context of memories to the central amygdala (Fudge and Tucker, 2009)
Amygdalohippocampal area	Emotional learning and memory (McDonald and Mott, 2017)
Amygdalohippocampal transition area	Sociosexual behavior and cognitive functions ( Sedwick and Autry, 2022)
Amygdaloatrial transition area	Fear learning under stress (Goto et al., 2022)
Basal nucleus	The bridge between the lateral (input) and central amygdala (output), is involved in fear expression and extinction (Amano et al., 2011), contextual control after fear extinction (Orsini et al., 2011), learning active fear coping responses (Phelps and LeDoux, 2005)
Central nucleus	Main output region, behavioral and autonomous fear responses (Phelps and LeDoux, 2005), feedback to the lateral amygdala (Yu et al., 2017)
Cortical nucleus	Aversive and appetitive odor-driven behavior ( Root et al., 2014), selective processing of social stimuli (Goossens et al., 2009)
Endopiriform nucleus	/ <sup>a</sup>
Intercalated nucleus	Regulates switch between low- and high-fear states (Hagihara et al., 2021), relay function in the expression of fear extinction (Likhtik et al., 2008)
Intramedullary gray of the amygdala	/ <sup>a</sup>
Lateral nucleus	Sensory input, key site of plasticity (Phelps and LeDoux, 2005)
Medial nucleus	Olfactory processing, innate emotional behavior for reproduction and defense (Keshavarzi et al., 2014), processing social signals, and regulating social behavior (Raam and Hong, 2021)
Paralaminar nucleus	Close to projections involved in contextual fear learning (deCampo and Fudge, 2012)

Annotations. a subnuclei have not been an object for research yet, nor have been explicitly functionally described in previous publications.

structural or functional connectivity, seven articles on depression, one article each on bipolar disorder, psychotic disorders, autism, and sexual dysfunctions, and three articles on neurological disorders.

## 3. Advances in high-field imaging: benefits for amygdala research

Typically, the properties of the human amygdala are investigated using functional or structural magnetic resonance imaging. Most studies



**Fig. 1.** Schematic illustration of the subnuclei of the left human amygdala. From left to right, the amygdala is shown in an anterior, medial, and posterior frontal section, viewed from an anterior perspective. White areas show undescended amygdala matter. AA = anterior amygdala area; AB = accessory basal (or basomedial) nucleus; ACTA = amygdalocortical transition area; AHA = amygdalohippocampal area; AHTA = amygdalohippocampal transition area; ASTA = amygdaloatrial transition area; BA = basal nucleus; Ce = central nucleus; Co = cortical nucleus; En = endopiriform nucleus; INA = intercalated nuclei; IMG = intramedullary gray of the amygdala; LA = lateral nucleus; Me = medial nucleus; PL = paralaminar nucleus. Based on the cellular-resolution atlas by Ding et al. (2016).

**Table 2**

Volumes of amygdala subnuclei of the left and right hemisphere in healthy adult subjects.

Nucleus	Roddy et al. (2021)	Cui et al. (2020) <sup>a</sup>	Zuo et al. (2023)
Whole amygdala	R 1734 ± 12 <sup>b</sup> L 1699 ± 13	R 1859.253 ± 168.184 <sup>c</sup> L 1815.260 ± 174.344	
Anterior amygdalar area	R 56.30 ± 0.74 L 53.81 ± 0.67	R 64.180 ± 6.641 L 60.381 ± 6.779	R 65.6 ± 8.5 <sup>c</sup> L 62.4 ± 8.2
Accessory basal nucleus	R 259.69 ± 2.12 L 254.11 ± 2.12	R 283.288 ± 25.640 L 275.435 ± 31.274	R 292.0 ± 38.5 L 290.3 ± 35.8
Amygdalocortical transition area	R 193.00 ± 1.72 L 192 ± 1.8	R 188.620 ± 19.389 L 190.128 ± 26.655	R 191.2 ± 25.0 L 198.3 ± 25.1
Amygdalohippocampal area			
Amygdalohippocampal transition area			
Amygdalostriatal transition area			
Basal nucleus	R 430.91 ± 3.20 R 422.39 ± 3.40	R 478.559 ± 45.965 L 468.220 ± 47.291	R 486.7 ± 59.0 L 481.9 ± 55.2
Central nucleus	R 46.58 ± 0.94 L 45.40 ± 0.78	R 46.013 ± 5.886 L 42.654 ± 6.794	R 48.6 ± 9.4 L 45.2 ± 8.8
Cortical nucleus	R 26.96 ± 0.41 L 24.77 ± 0.44	R 29.276 ± 3.349 L 27.368 ± 3.429	R 29.2 ± 4.9 L 29.5 ± 5.0
Endopiriform nucleus			
Intercalated nucleus			
Intramedullary gray of the amygdala			
Lateral nucleus	R 652.81 ± 5.02 L 642.59 ± 5.79	R 692.813 ± 65.799 L 676.520 ± 65.766	R 712.1 ± 81.7 L 693.3 ± 82.0
Medial nucleus	R 20.64 ± 0.60 L 19.70 ± 0.64	R 24.000 ± 4.893 L 21.452 ± 3.815	R 24.5 ± 6.3 L 23.8 ± 6.3
Paralaminar nucleus	R 50.93 ± 0.43 L 50.52 ± 0.51	R 52.502 ± 5.646 L 53.101 ± 5.820	R 53.1 ± 6.5 L 54.5 ± 6.5

Annotations. Volumes are presented in mm<sup>3</sup> controlled for intracranial volume. No data was found on the amygdalohippocampal (transition) area, amygdalostriatal transition area, endopiriform and intercalated nuclei, nor the intramedullary gray of the amygdala. R = right hemisphere, L = left hemisphere. a Pediatric study, mean age = 14.37 ± 1.30 years; b mean ± standard error of the mean; c mean ± standard deviation.

apply magnetic field strengths between 1.5 T (Tesla) (Cheng et al., 2003; Evans et al., 2008; Orihashi et al., 2020) and 3 T (Gryglewski et al., 2019; Kraff et al., 2015; Wen et al., 2022). While this method is economical and convenient, these studies often fail to identify small substructures of the amygdala and adjacent areas due to their low spatial resolution (Faull et al., 2015). Traditionally, structural images are acquired at 1 mm isotropic or higher, while for fMRI, resolutions between 2 and as low as 4 mm isotropic are used. Diffusion MRI is often recorded with a resolution of 2–2.5 mm isotropic. In contrast, 7 T imaging enables data acquisition with higher resolutions, (Glasser et al., 2016), not only providing more information on subnuclei of the amygdala but also overcoming issues like interferences in ventral brain regions from visceral activation and low sensitivity for field-inhomogeneities (Sladky

et al., 2018, 2013). The combination with nuisance regressors enables canceling out strong temporal signal fluctuations in ventral regions of interest. Sladky et al. (2013) demonstrated the superiority of ultra-high field imaging in terms of better temporal and spatial resolution, a 100% signal increase, and better contrast. They compared bilateral amygdala activation during an emotion task and an object recognition task between fMRI using a 7 T MRI scanner and a 3 T MRI scanner. The increased contrasts and higher temporal and spatial resolution of 7 T imaging allow for more reliable measures on the submillimeter level due to smaller voxels (usually between 0.3 mm and 1.0 mm isotropic; Keuken et al., 2018).

The most frequently used ultra-high field strength is 7 Tesla, enabling investigations of voxel sizes even up to 0.2 × 0.2 × 0.2 mm (Siemens Healthcare GmbH, 2022). Structural investigations mostly use T1-weighted MP2RAGE sequences with isotropic 0.7–0.9 mm voxels, while functional scans were preferably conducted using T2-weighted FLAIR or EPI sequences with a spatial resolution between 0.47 × 0.47 × 3 mm and isotropic 1.5 mm voxels. For investigations of multiple regions, the most common procedure for correcting for multiple comparisons are the family-wise error rate (FWE) and the false discovery rate (FDR). Currently, novel algorithms for FDR correction are being developed, like the Local Indicators of Spatial Association (“LISA”), which has been shown to be more sensitive and spatially specific than other methods used for ultra-high field imaging with 7 T or above (Lohmann et al., 2018). In the investigations reviewed in the present article, the most frequently applied methods for correction for multiple comparisons were FEW (e.g., 3dClustSim), FDR, Bonferroni-Holm, Benjamini-Hochberg, and Tukey’s method.

Ultra-high field imaging is currently used to investigate fear extinction (Batsikadze et al., 2022), addiction (Brand et al., 2016), and neuroendocrinology (Thielen et al., 2019), and is discussed as a promising tool for tumor localization (Patel et al., 2020). Since the amygdala is parcellated in subnuclei less than a millimeter in diameter, ultra-high field imaging seems obligatory for the reliable investigation of these substructures, as well. In the following sections, we will briefly review the literature on ultra-high field imaging of the amygdala with a field strength of 7 T or larger.

## 4. High-field imaging of the amygdala in non-clinical samples

### 4.1. Studies on functional activation of the amygdala

Ultra-high field imaging of the amygdala has been predominantly used in clinical studies. In non-clinical investigations, research has been done on functional and structural connectivity and functions of the amygdala. One of the earliest functional ultra-high field amygdala studies was published by Sladky et al. (2013). They aimed to investigate activation in the amygdala and BNST during the processing of emotional faces and found increased activation in the central and basolateral amygdala and the BNST in response to visual emotion processing. Later, Huggins et al. (2021) conducted a 7 T fMRI investigation on the neural substrates of fear generalization by presenting Gabor patches as visual stimuli in different angles varying between the angle of the secure CS- and the fearful CS+ which was followed by electric stimulation. They found a marginal negative fear generalization gradient (i.e., less activation due to high CS+ similarity) for the basal, but not the centromedial or lateral amygdala. Because of the small size of the BNST, Pedersen et al. (2017) used 7 T fMRI to visualize the effects of novelty, valence, and trait anxiety in the BNST, amygdala, and hippocampus. The hippocampus’ response to the novelty of faces was independent of emotional valence. The BNST selectively responded to the novelty of only neutral faces whereas the amygdala only responded to the negativity of the faces. Interestingly, all these responses were blunted by high trait anxiety. Also, although barely not statistically significant, the authors found an interesting trend towards an inter-hemispheric contrast: The right amygdala was more strongly activated when novel faces were

fearful relative to neutral, while repeated faces elicited higher activation when they were neutral vs. fearful. The left amygdala exhibited an opposite pattern. Furthermore, reduced sensitivity to negativity due to high anxiety was limited only to the left amygdala. In a later study, the group around Pedersen demonstrated that the BNST, but not the centromedial amygdala, plays a crucial role in anxious anticipation of aversive stimuli (Pedersen et al., 2019). Adding to the evidence on aversive stimuli, Robertson et al. (2022) examined signal changes in the hypothalamus, amygdala and periaqueductal gray matter in response to acute noxious orofacial stimuli. They found significant signal decreases in the lateral, basolateral, dorsal basolateral, and basomedial nucleus contralateral to the heat stimuli.

Kreuder et al. (2020) studied the association between anxiety and fearful face processing from a neurochemical perspective. In their ultra-high field fMRI study, they found oxytocin and lorazepam to blunt the response of the centromedial amygdala to fearful vs. neutral faces. Both neuromodulators changed the intra-amygdalar connectivity of the centromedial, basolateral and superficial (cortical) amygdala, whereas only oxytocin affected the connectivity between the centromedial amygdala and cortical structures. They concluded that anxiolytic medication may work by reducing amygdala activity and changing its connectivity.

Kragel et al. (2021) provided evidence for a functional colliculus-pulvinar-amygdala pathway encoding the intensity of normative emotional responses to negative emotional stimuli on the 7 T level. They suggested that this pathway portrays a functional “low road” processing of visual and auditory information. Aiming to validate these ultra-high field functional imaging results into context, Geissberger et al. (2020) investigated the systematic replicability of the bilateral amygdala activation in response to emotional faces. In each test run under varying experimental conditions, they were able to replicate the findings, and concluded that 7 T fMRI enables the mapping and parcellation of the amygdala in various ways in clinical and non-clinical settings.

In contrast to the validation of emotion processing studies by Geissberger et al. (2020), Murphy and colleagues (2020) conducted a methodological study on the limitations of ultra-high-field imaging. They investigated the validity of the results of activation patterns in the amygdala during a face-matching task using fMRI at 7 T, which were obtained by different spatial preprocessing steps. The combination of smoothing and motion correction yielded significantly different results. Specifically, differences in motion correction especially led to changes in the laterality of the activation in the amygdala and other subcortical and limbic structures. Thus, the authors uncovered a critical factor in the reproducibility of fMRI results on submillimeter resolution and put mixed results in ultra-high field studies in a new light.

#### 4.2. Connectivity studies

In an extensive connectivity study by Klein-Flügge et al. (2022), all amygdala nuclei showed strong functional connectivity with the ventral caudal, medial frontal, and caudal orbitofrontal cortex. However, the basal and cortical amygdala had the strongest functional connectivity with those areas and negative correlations with lateral prefrontal regions, whereas the central nucleus was most strongly connected to subcortical and brainstem regions, underlining its role in autonomous activation in response to fearful stimuli. The connectivity between the lateral amygdala and the medial prefrontal cortex was identified as the strongest predictor for life satisfaction. Low functional connectivity between the basal amygdala and medial prefrontal regions and high connectivity between the central nucleus and subcortical areas were correlated to sleep problems. Furthermore, anger/rejection experience was associated with a lower negative correlation between the cortical amygdala and subcortical regions as well as between the lateral nucleus and cortical areas. Finally, negative emotion scores were predicted by functional connectivity between the nucleus accumbens and the basal and basomedial amygdala, and between the locus coeruleus and the

lateral amygdala. In general, networks including the basal, cortical, and central amygdala were positively correlated with negative emotions. Further, Ince et al. (2023) investigated the role of the whole amygdala in negative emotional processing using ultra-high field imaging. They found the amygdala to amplify the activation of a network encoding negative emotional salience. Conversely, the response was inhibited by activation of the periaqueductal grey matter which they hypothesized to be mediated by input from the amygdala. They concluded that the amygdala and periaqueductal grey matter play opposing modulating roles in negative emotion processing.

Busler et al. (2019) examined functional connectivity patterns of the posterior cingulate cortex (PCC) and found, among other areas, the bilateral amygdalae to be co-activated and the left amygdala to be co-deactivated with the PCC. The authors assume a functional network for emotion processing in which the left amygdala is involved in processing fearful stimuli. Sladky et al. (2022) studied the role of the orbitofrontal (OFC), the ventromedial (vmPFC) and dorsolateral prefrontal cortex (dlPFC) in the amygdala during processing of emotional faces. They found that the OFC, but not the vmPFC or the dlPFC, is crucial in the downregulation of the amygdala during processing of emotional faces. They suggest that this association may be causal in the pathophysiological processes underlying mental disorders.

Gorka et al. (2018) investigated the intrinsic functional connectivity of the main output region of the amygdala, i.e., the central nucleus, and the bed nucleus of the stria terminalis. They demonstrated that both regions connect to areas of the middle prefrontal cortex, the hippocampus, the thalamus, and the mesencephalic periaqueductal grey (PAG). The CeA (central nucleus of the amygdala) was more extensively coupled with the insula and sensory regions (i.e., thalamus and PAG) than the BNST, whereas the BNST was more closely connected to motivational and cognitive areas like the dorsal paracingulate cortex, the posterior cingulate cortex, and the striatum. Interestingly, these amygdalar structures showed asymmetric connectivity patterns: Overall, the left CeA was more extensively connected than the left BNST, while the right BNST was more connected than the right CeA. Further, the left CeA was more strongly connected than the right CeA. In an investigation of the functional connectivity of the BNST and central amygdala, Tillman et al. (2018) discovered significant functional connectivity between the central amygdala and widespread frontal and prefrontal cortex areas. These included the cingulate cortex, temporal areas, the insula, parietal, as well as the lateral occipital, and fusiform gyrus. The BNST was more strongly connected to the thalamus, striatum, periaqueductal gray, the cingulate, and other prefrontal areas. Furthermore, both structures were functionally connected to the anterior hippocampus. Torrisi et al. (2017) found functional connections between the habenula and the BNST, nucleus basalis, dorsal Raphé's nucleus, the ventral tegmental area, the PAG, the caudate nucleus, the thalamus, and cortical areas. In a 2018 study investigating the functional connectivity of the extended amygdala in shock anticipation, the group found a decreased coupling between the central amygdala and BNST with the vmPFC, cingulate, and the nucleus accumbens in anticipation of electric stimulation (Torrisi et al., 2018). Weis et al. (2019) examined the role of the extended amygdala's connectivity pattern in anxiety. They found the CeA and BLA to be strongly connected with parahippocampal, temporal, fusiform, and occipital areas, whereas the BNST appeared more strongly connected to the anterior caudate and cingulate cortex. Altogether, they could not give definite evidence of the relationship between the amygdala, trait anxiety, and tolerance of uncertainty.

Investigating the functions of the thalamus' paraventricular nucleus, Kark et al. (2021) found involvement of the amygdala in a network involved in episodic memory consolidation that they associated with the default mode network. In a functional 7 T parcellation study, Zhang et al. (2018) identified the centromedial, laterobasal, and superficial complexes as subregions that are functionally homogenous within themselves. They found correlations with various brain regions

including cortical areas, basal ganglia, medial temporal lobes, limbic structures, and the cerebellum. The authors emphasized the role of the centromedial nucleus as the main output region for autonomous and motor functions. Further, they suggested the laterobasal amygdala to be crucial for high-level visual processing and significance detection, associative learning, and the superficial nucleus for social interaction. Interestingly, some subnuclei of the amygdala show hemispheric asymmetries in connectivity. Functional connectivity asymmetries were found mainly in the centromedial amygdala. In a structural 7 T study, [Derix et al. \(2014\)](#) found inter-hemispheric and interindividual variability of the amygdala-hippocampal border. This association was not further explained. However, it underlines the feasibility of ultra-high field imaging in investigating microstructural differences in substructures of the amygdala and adjacent areas.

Surprisingly, only little evidence is available about intra-amygdala connectivity using ultra-high field imaging. From lower-field strength research, we know that the subnuclei of the amygdala are intrinsically connected, both functionally and structurally. For example, the centromedial, lateral, and basal amygdala are functionally interconnected with strong associations between the basal and lateral, and between the basal and centromedial nuclei ([Hrybowski et al., 2016](#)). Also, since it is the main input structure of the amygdala, the lateral amygdala conveys external information to other subnuclei which are ultimately passed on to the central amygdala as the main output interface of the amygdala. However, on the 7 T level, no study to date has explicitly investigated the intrinsic connectivity among the amygdala subnuclei in between. For the extended amygdala, [Torrise et al. \(2018\)](#) identified a positive coupling between the BNST and the central and dorsal amygdala which they interpreted as relevant to threat anticipation. [Weis et al. \(2019\)](#), on the other hand, could not find a high correlation between the BNST and the central or basolateral amygdala, but a strong connectivity between the basolateral and central amygdala. Altogether, the connectivity among the subnuclei has not been extensively investigated.

## 5. High-field imaging of the amygdala in psychiatric disorders

### 5.1. Major depressive disorder

Most clinical ultra-high field MRI studies of the amygdala investigated MDD. Several studies found decreased volumes of subnuclei of the left and right amygdala. In a recent review article, Cattarinussi and colleagues (2021) summarized 13 ultra-high field MRI studies on MDD. They describe inconsistent evidence for amygdala abnormalities in MDD: while most studies had found structural connectivity alterations, the literature on volumetric differences was still ambiguous. For example, using 7 T structural MRI, [Brown et al. \(2019\)](#) found the volumes of the bilateral centrocortical complexes and corticoamygdaloid transition area, the right lateral nucleus, and basolateral complex, and the left cortical and accessory basal nuclei to be negatively correlated with depressive symptom severity. The authors suggested a link between depressive symptoms and volume reduction in amygdala substructures of both hemispheres. This is in line with research from lower-field strength imaging studies. On the 3 T level, decreased volumes of the right lateral and anterior amygdala as well as the whole right amygdala were found in MDD patients. In contrast, a 7 T study by [Roddy et al. \(2021\)](#) revealed increased rightward amygdala asymmetry in MDD that was driven by the right medial nucleus. Furthermore, the volume of the left cortico-amygdalar transition area was negatively correlated with the cortisol awakening response which, however, did not differ between patients and healthy controls. Lastly, in an antidepressive treatment study by [Kraus et al. \(2019\)](#), MDD patients showed an enlarged right amygdala-hippocampal transition area and hippocampal fissure. Monoaminergic antidepressants as used in the study by Kraus et al. did not change these volumetric alterations. [Brown et al. \(2020\)](#) found increased structural connectivity of right lateral, basal, central, and centrocortical amygdala nuclei in MDD patients compared to healthy

controls. These increases in connection density were driven by parts of the right stria terminalis and the right uncinate fasciculus. The left medial amygdala showed decreased connectivity. Since the central nucleus' projections to the hypothalamus are usually associated with stress responses ([Kalin et al., 2004](#)), the authors assume a link to the dysregulated reactivity to stress found in depressive patients. Consistent with these findings, [Jacob et al. \(2022\)](#) found the degree of functional connectivity of the right central amygdala to correlate with depressive symptom severity. Altogether, while the state of research remains uncertain, these results suggest a relationship between bilaterally altered amygdala volumes, increased right-sided connectivity, and depression.

### 5.2. Bipolar disorder

In addition to unipolar depression, the amygdala, along with other limbic structures, is also affected in bipolar disorder in terms of volume and structure (see [Athey et al., 2021](#)). To our best knowledge, [Athey et al. \(2021\)](#) were the only group to date to investigate structural changes in the hippocampi and amygdalae following lithium therapy at the 7 T level. They did not find volumetric alterations in the amygdala or hippocampi when comparing bipolar patients and healthy controls.

### 5.3. Psychotic disorders

Other studies have investigated amygdala involvement in psychotic disorders using ultra-high field imaging. [Mahon et al. \(2015\)](#) used 7 T parcellation of the amygdala to identify morphologic features of subregions which distinguish the neuronal basis of psychotic episodes in bipolar disorder from psychotic symptoms in schizophrenia. Unlike [Athey et al. \(2021\)](#), they focused on the psychotic experience in bipolar disorder, rather than the affective symptoms. Mahon et al. found significant atrophy of the left basolateral, basomedial, and centromedial amygdala in schizophrenia as compared to psychotic bipolar disorder. The right amygdala was atrophied in schizophrenia in comparison to psychotic bipolar disorder. Results for the right amygdala indicate a trend towards atrophy in schizophrenia and increased volume in psychotic bipolar disorder as compared to healthy controls.

### 5.4. Autism

Ultra-high field imaging has also proven useful to detect microstructural alterations in pathology. [Fischi-Gomez et al. \(2021\)](#) aimed to identify histopathological changes in autism spectrum disorder. They were able to visualize an increased grey matter density and abnormal laminar cytostructure in the bilateral amygdala and the right lateral orbitofrontal cortex in-vivo.

### 5.5. Sexual dysfunctions

Finally, in a 7 T graph analytical connectivity study, [Chen et al. \(2020\)](#) found the left amygdala's local efficacy to be negatively associated with premature ejaculation, state anxiety, and penile shaft sensitivity.

The findings on amygdala alterations in psychopathology summarized above show that 7 T imaging can discover processes in the amygdala that lower field strength imaging is not capable to detect. For example, in psychotic disorders, ultra-high field imaging revealed atrophy of specific amygdala subregions that could not be observed using 1.5 T imaging. Further, the negative correlation between depressive symptom severity and volumes of specific amygdala substructures contrasts earlier low-field strength findings. In general, 7 T imaging yields findings that not only complement but also correct the picture of amygdala involvement in psychopathology.

## 6. High-field imaging of the amygdala in neurological disorders

Other ultra-high field studies investigated amygdala involvement in various neurological disorders. For instance, [Alper et al. \(2021\)](#) aimed to assess structural alterations in trigeminal neuralgia using 7 T MRI. They targeted subcortical structures associated with stress and pain (i.e., amygdala, hippocampus, and thalamus) and found volume reduction of the basal and the paralaminar nucleus ipsilateral to the pain symptoms, alongside structural alterations in thalamic substructures. [Oh et al. \(2021\)](#) studied grey matter changes in patients with Parkinson's disease on a 7 T level. Besides prefrontal, hippocampal, and fusiform gyrus atrophy, there were significant volume reductions in the right, but not the left amygdala in patients with Parkinson's disease. Another 7 T study with drug-resistant epilepsy patients revealed an enlarged amygdala to be part of the epileptogenic zone in different subcortical and cortical networks ([Makhalova et al., 2022](#)). Contrary to the above-described findings, bilateral amygdala hypertrophy was positively correlated with depressive symptoms. These findings may be limited to epilepsy with depressive symptoms as comorbidity. Altogether, these results suggest an inconsistent involvement in neurological and psychopathological etiology models. Since these were the only ultra-high field studies on the amygdala that we were able to find, the evidence on neurological disorders and psychopathology (aside from MDD) is still sparse.

## 7. Discussion

The amygdala is a highly complex structure with a small overall volume. Ultra-high field imaging of the amygdala is, thus, indispensable to reliably investigate questions concerning clinic, connectivity, and function, since effects have been found on the subnuclear level. Therefore, the present work aimed to review recent studies on high-field

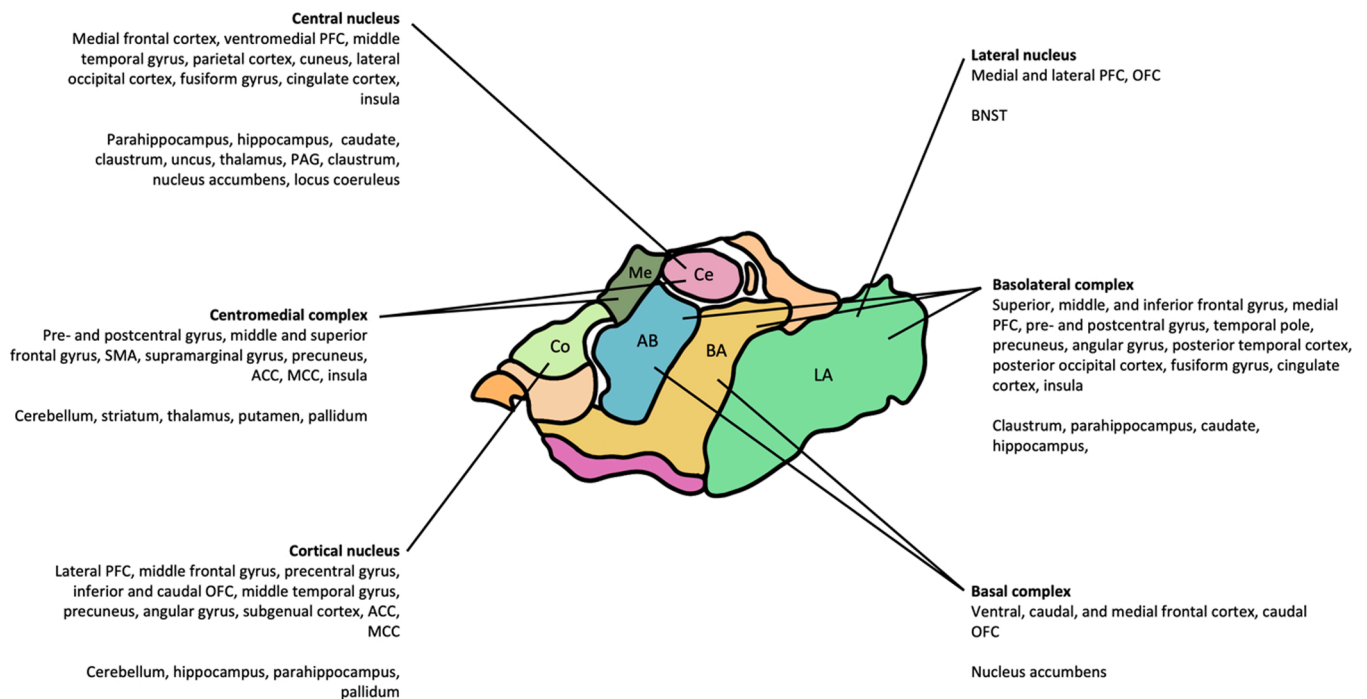
imaging in the amygdala and synthesize their insights into the amygdala's connectivity, activity, and clinical relevance.

Using high-field imaging, evidence that was previously gathered on the whole amygdala can now be narrowed down to individual subnuclei or complexes and adjusted for confounding effects from other subnuclei. The current state of ultra-high field imaging research is largely in line with lower-field findings and complements it with evidence on individual subnuclei. The findings presented above can be categorized as functional, connectivity, and clinical evidence. For a summary of nucleus-specific findings, see [Table 2](#).

The studies shed light on the role of specific subnuclei of the amygdala, including the central, basal, and basolateral amygdala as well as the BNST, in different aspects of the processing of emotions, fear, and potentially aversive stimuli. Furthermore, hemispheric asymmetries in the processing of stimulus valence and novelty were found. Interestingly, however, no ultra-high field study replicated the involvement of the lateral nucleus as an input interface for potentially aversive stimuli in fear learning.

Additionally, the reviewed literature provides evidence for the involvement of the amygdala in different neuronal networks. For the results regarding functional connectivity, see [Fig. 2](#). The studies suggest that the amygdala is involved in networks associated with emotion processing, memory consolidation, cognitive and motivational processes, significance detection, and associative learning. Subnuclei relevant in these functional networks include the centromedial amygdala and the superficial and laterobasal complex. However, to date, there is no literature on the functional connections between the subnuclei of the amygdala. ([Table 3](#)).

Regarding clinical aspects, the studies particularly focused on MDD with inconsistent findings on volumetric differences between patients and healthy controls. Only few studies have investigated alterations in the amygdala in other diseases, such as psychotic disorders, ASD, bipolar



**Fig. 2.** Schematic illustration of the functional connectivity of subnuclei of the human amygdala. The connections are grouped into cortical (upper list) and subcortical (lower list) areas. The basal complex comprises the basal and the accessory basal nucleus ([Klein-Flügge et al., 2022](#)). The basolateral (or laterobasal) complex includes the lateral, basal, and accessory basal nucleus ([Weis et al., 2019; Zhang et al., 2018](#)). The centromedial complex comprises includes the central and medial nucleus ([Zhang et al., 2018](#)). AB = accessory basal amygdala; ACC = anterior cingulate cortex; BA = basal amygdala; BNST = bed nucleus of the stria terminalis; Ce = central amygdala; Co = cortical amygdala; LA = lateral amygdala; MCC = medial cingulate cortex; Me = medial amygdala; OFC = orbitofrontal cortex; PAG = periaqueductal gray; PFC = prefrontal cortex; SMA = supplementary motor area. ([Gorka et al., 2018; Klein-Flügge et al., 2022; Tillman et al., 2018; Torrisi et al., 2018; Weis et al., 2019; Zhang et al., 2018](#)).

**Table 3**  
Overview of ultra-high field research findings on amygdala subnuclei.

Nucleus	Findings
Anterior amygdalar area	Decreased volume in MDD (right; Kim et al., 2021)
Accessory basal nucleus	Decreased volume in MDD (left; Brown et al., 2019) Connectivity with the nucleus accumbens predicted negative emotions (Klein-Flügge et al., 2022) More strongly atrophied in schizophrenia than in psychotic bipolar disorder (Mahon et al., 2015)
Amygdalocortical transition area	Decreased volume in MDD (bilateral; Brown et al., 2019) Negatively correlated with the cortisol awakening response (left; Roddy et al., 2021)
Amygdalohippocampal area	<i>No ultra-high field findings</i>
Amygdalohippocampal transition area	Increased volume in MDD (right; Cattarinussi et al., 2021) Inter- and intraindividual variety (Derix et al., 2014) Increased volume in MDD (right; Kraus et al., 2021)
Amygdalostratial transition area	<i>No ultra-high field findings</i>
Basal nucleus	Decreased volume in trigeminal neuralgia (Alper, 2021) Increased connectivity in MDD (right; Brown, 2020) Decreased volume in MDD (right; Brown, 2019) Negative fear generalization gradient (Huggins et al., 2021) Low connectivity with medial PFC predicted sleep problems; connectivity with nucleus accumbens predicted negative emotions (Klein-Flügge et al., 2022) <i>Basolateral &amp; basomedial</i> atrophied more in schizophrenia than in psychotic bipolar disorder (Mahon et al., 2015) <i>Basolateral, dorsal basolateral &amp; basomedial:</i> decreased signal in response to noxious heat stimuli (Robertson et al., 2022) <i>Basolateral:</i> visual emotion processing (Sladky et al., 2013) <i>Laterobasal:</i> significance detection and associative learning (Zhang, 2018)
Central nucleus	Noiception, left anti-nociceptive (Allen et al., 2021) Increased structural connectivity in MDD (right; Brown, 2020) Bilateral centrocorticoid and left central volumes negatively correlated with depressive symptom severity (Brown et al., 2019) Coordination of responses to sensory stimulation (Gorka et al., 2018) Functional connectivity correlates with depressive symptom severity (right; Jacob et al., 2022) Stress response (Kalin et al., 2004) Involved in networks correlating with negative emotions; strong connectivity with subcortical and brainstem regions; high connectivity with subcortical areas predicted sleep problems (Klein-Flügge et al., 2022) OXT and LZP inhibit response to fearful faces. OXT increases connectivity with BLA, dmPFC, and preceunus. LZP increases the connectivity of the left centromedial with the right SFA (Kreuder et al., 2020). Stronger atrophy in schizophrenia than in psychotic bipolar disorder (Mahon et al., 2015) Visual emotion processing (Sladky et al., 2013) Functionally connected with widespread frontal and prefrontal cortex areas and the anterior hippocampus (Tillman et al., 2018) Decreased coupling with the vmPFC, cingulate, and the nucleus accumbens in anticipation of electric stimulation (Torrissi et al., 2018) Centromedial: Main output region for autonomous and motor functions (Zhang et al., 2018)

**Table 3 (continued)**

Nucleus	Findings
Cortical nucleus	Decreased volumes in MDD (left; Brown et al., 2019) Increased structural connectivity in MDD (right; Brown et al., 2020) Low negative connectivity with subcortical regions predicted feelings of anger/rejection; involved in networks for negative emotions (Klein-Flügge et al., 2022) LZP enhances functional connectivity between the left centromedial and right superficial complex in response to fearful faces (Kreuder et al., 2020) Superficial complex: olfactory information, social interaction (Zhang et al., 2018) <i>Centrocorticoid complex: see "Central amygdala"</i>
Endopiriform nucleus	<i>No ultra-high field findings</i>
Intercalated nucleus	<i>No ultra-high field findings</i>
Intramedullary gray of the amygdala	<i>No ultra-high field findings</i>
Lateral nucleus	Decreased volume in MDD (right; Brown, 2019) Increased connectivity in MDD (right; Brown, 2020) Connectivity with the medial prefrontal cortex predicted life satisfaction; low connectivity with cortical areas during anger/rejection; connectivity with locus coeruleus predicted negative emotions (Klein-Flügge et al., 2022) Decreased signal in response to noxious heat stimuli (Robertson et al., 2022) <i>Basolateral complex: see "Basal nucleus"</i>
Medial nucleus	Decreased connection density in MDD (left; Brown, 2020) Enlarged in MDD (right; Roddy et al., 2021) <i>Centromedial complex: see "Central nucleus"</i>
Paralaminar nucleus	Decreased volume in trigeminal neuralgia (Alper, 2021)

Annotations. BLA = basolateral amygdala; dmPFC = dorsomedial prefrontal cortex; LZP = Lorazepam; OXT = Oxytocin; SFA = superficial amygdala (composed of the cortical amygdala and olfactory nucleus).

disorder, Parkinson's disease trigeminal neuralgia, and epilepsy.

Interestingly, the study by Murphy et al. (2020) was the only one to explicitly address amygdalar functional and structural asymmetries with high-resolution MRI, although hemispheric differences have been found as "byproducts" in many analyses. A comprehensive review article by Ocklenburg et al. (2022) underlines the amygdala's asymmetric properties in terms of structure, function, connectivity, and clinical relationships. In general, the amygdala shows a robust volumetric rightward asymmetry which is mainly driven by a larger rightward asymmetry of the lateral nucleus, while other subnuclei show different patterns of lateralization. Further, there is evidence of leftward dominance for positively perceived stimuli (Young and Williams, 2013) and right-hemispheric dominance in processing negative emotional valence (Palomero-Gallagher and Amunts, 2021). Of note, this contrasts with the above-described 7 T-findings in suggesting that the right rather than the left amygdala is crucial in recognizing fearful stimuli. Additional confounding effects in emotion processing studies may arise from the supposed leftward dominance for emotional language and a rightward dominance for visual emotional stimuli in the amygdala (Markowitsch, 1998). Moreover, temporal dynamics of the experiments are suspected to influence the amygdala's responses: the right amygdala may be more active when stimuli are presented for sustained, long durations and cognitive processing, whereas the left amygdala may be dominant for short-term presentation and automated, subconscious processing. Ocklenburg et al. (2022) summarized this in three factors that are causal to the heterogeneous findings on amygdala asymmetry. They define a multimodal "TEP approach" with the factors being the temporal dynamics of experimental paradigm (T), the emotional valence of stimulus material (E), and perceptual stimulus properties (P). Thus, it appears necessary to manipulate these factors in functional and structural

ultra-high field investigations and to link the structural asymmetries in terms of volume and structural connectivity to the functional asymmetries to obtain an overall, integrative picture.

## 8. Implications for future research

High-field imaging of the amygdala is still an emerging field in clinical and basic neuroscience, and the results of the studies presented in the previous sections hold several implications for future research projects. Due to differences in hemispheric asymmetries between subnuclei, it is imperative to study the amygdala's functional and structural asymmetries on a deeper level including the functional and structural internal organization of the amygdala instead of viewing it as a whole structure.

From conventional fMRI studies, we know intra-amygdaloid pathways and connectivity patterns that mirror the anatomical structure of the amygdala. For example, using 3 T imaging, (Grant et al., 2015) observed a robust causal functional pathway originating in the right basolateral amygdala, targeting the left and right superficial complex. This is in line with the lateral amygdala being the main input structure of the amygdala, conveying converging sensory input from cortical areas and the thalamus to the basal nucleus which, in turn, sends efferent projections to the central amygdala as the main output station to the hypothalamus and the periaqueductal gray (LeDoux, 2007; McDonald, 2020). Additionally, Grant et al. (2015) found another pathway from the right superficial to the left basolateral amygdala. However, these investigations only examined the amygdala subdivisions as clusters rather than individual subnuclei. Therefore, investigating the role of smaller subnuclei like the cortical or medial amygdala or the transition areas could shed new light on the internal organization of the amygdala, as it may discover unknown intra-amygdalar connections. Ultra-high field imaging may prove itself very useful in detecting potential connections on subnuclear level. Instead of merely functional analyses, Oler et al. (2016) examined the structural and functional connectivity of the central extended amygdala (i.e., BNST, central nucleus, and sublentiform extended amygdala) using both structural and functional in vivo connectivity measures and ex vivo tract tracing in non-human primates across the early life. While they found a constantly strong white matter tract connecting the BNST and the central nucleus to the sublentiform extended amygdala, the functional connectivity between the central amygdala and the BNST increased over time. Moreover, Sawada et al. (2022) used both electrical stimulation fMRI and tract tracing via intracranial electroencephalography to explore brain-wide networks with reciprocal connections to the lateral nucleus and a medial nuclear complex. They found widespread cortical network nodes with differentially evocable potentials between lateral and medial amygdala stimulation. Even though these studies do not fully meet our search criteria, both show the importance and potential of multimodal research on the amygdala's intrinsic and extrinsic connectivity which could be complemented by ultra-high field imaging in future research. Altogether, it seems reasonable that this approach may solve the inconsistencies and replicability issues of findings on amygdala asymmetries.

Like psychology, neuroscience faces a severe replication and reproducibility crisis (Milkowski et al., 2018). Apart from theory-driven suggestions like differential subnuclear influences on whole amygdala function, further questions related to replicability remain significantly under-researched in high-field amygdala imaging. Specifically, methodological peculiarities of high-field imaging must be considered. Different preprocessing methods have been shown to drastically influence functional imaging results and should be taken into account when comparing and interpreting findings. Also, researchers should make sure to report the precise MRI methods to facilitate replicability and comparability. These considerations may counteract a portion of the inconsistent results and must, thus, be established as soon as possible in the still young field of ultra-high field imaging.

To answer the open questions in the current literature, it appears crucial to study the structural and functional properties and connectivity of the amygdala under consideration of the TEP approach. To vary the modality and valence of stimulus material, future investigations could compare responses to positive, negative, or neutral faces or images, the latter taken from the International Affective Picture System, for instance (Lang et al., 1997). Additionally, auditory and written stimuli of varying valence should be included to obtain separate results for different modalities of language processing. For the temporal dynamics, the level of awareness of processing could be manipulated using backward masking (Gläscher and Adolphs, 2003; Morris et al., 1998). To minimize confounding effects due to hemispheric asymmetries in habituation rates of the two amygdalae, the stimuli should be presented in a randomized order. Once the three TEP variables are functionally associated with specific subnuclei, these could serve as regions of interest for analyses of volumetric properties and connectivity analyses of the amygdala. This way, researchers would be able to obtain a comprehensive image of how structural amygdala asymmetries give rise to functional asymmetries.

Given the high clinical relevance of the amygdala for affective and anxiety disorders, it will be crucial to understand how key factors involved in the pathogenesis of these disorders affect amygdala structure and function in high resolution. Only few studies have investigated the subnuclear microstructure of the amygdala in fear learning in humans. Schlüter et al. (2022) showed that neurite density in the lateral amygdala was correlated with neuroticism in humans. However, the parcellation did not fully succeed due to low spatial resolution at 3 T. Moreover, despite the asymmetric processing of emotional stimuli, the authors did not investigate interhemispheric differences. Thus, future studies should examine the microstructure and connectivity of all subnuclei on an ultra-high field level to apply the theoretical foundations of amygdala functioning to clinical research questions. Specifically, the amygdala's function as a relay for incoming emotional stimuli and further processing could be experimentally simulated with a fear conditioning paradigm or presentation of fearful faces while measuring the functional and structural connectivity and the BOLD response of individual subnuclei and their microstructure using Neurite Orientation Dispersion and Density (NODDI) analyses. Following this idea and previous 7 T findings, the interindividual neurite density in the lateral nucleus should correlate with the BOLD response of the lateral, basal, and central amygdala, as well as the BNST. For negative emotional stimuli, according to Palomero-Gallagher and Amunts (2021), these relationships should be stronger in the right than in the left hemisphere. However, a 7 T study by Busler et al. (2019) suggested a left-hemispheric dominance in processing fearful stimuli. This ambiguity remains to be resolved, as well.

In summary, future studies should apply ultra-high field MRI on theoretical considerations about hemispheric asymmetries in function, microstructure, and connectivity of amygdala subnuclei and systematically manipulate temporal characteristics, emotional valence, or perceptual properties of the stimuli to obtain a comprehensive overview of the determinants of subnuclear amygdala functioning, especially regarding hemispherical differences in functional activity. Combining these insights with structural and connective information could yield a holistic picture of the mechanisms underlying amygdala functions and psychopathological developments for example in anxiety disorders.

## 9. Conclusion

Taken together, the studies reviewed in the present article clearly show that ultra-high field imaging is an emerging field that offers new perspectives to study the underlying mechanisms of amygdala functions. The presented studies underline the important role and suggest interesting hemispherical asymmetries of the central, basal, basolateral, and extended amygdala in fear and emotion processing, and describe widespread connectivity patterns involving networks for learning and memory, stimulus processing, as well as cognitive and social processes.



Most clinical ultra-high field research in MDD patients suggests either an overall rightward atrophy of the amygdala or differential volume increases and decreases in different bilateral subnuclei, with the medial nucleus, conversely, driving a rightward enlargement of the amygdala. Structural alterations in other pathologies like bipolar affective disorder or psychotic disorders were found as well. However, the evidence on fear and emotion processing and connectivity on ultra-high field level is still sparse and ambiguous, partly due to methodological and conceptual differences, leaving room for further comprehensive investigations.

## Funding

O.G. was supported by the Deutsche Forschungsgesellschaft (grant number Gu 227/16-1).

## Declaration of Competing Interest

The authors declare no competing interests.

## References

- Adhikari, A., Lerner, T.N., Finkelstein, J., Pak, S., Jennings, J.H., Davidson, T.J., Ferenczi, E., Gunaydin, L.A., Mirzabekov, J.J., Ye, L., Kim, S.Y., Lei, A., Deisseroth, K., 2015. Basomedial amygdala mediates top-down control of anxiety and fear. *Nature* 527, 179–185. <https://doi.org/10.1038/nature15698>.
- Adolphs, R., Tranel, D., Damasio, H., Damasio, A., 1994. Impaired recognition of emotion in facial expressions following bilateral damage to the human amygdala. *Nature* 372, 669–672.
- Adolphs, R., Tranel, D., Damasio, A.R., 1998. The human amygdala in social judgment. *Nature* 393, 470–474.
- Aleman, A., Kahn, R.S., 2005. Strange feelings: do amygdala abnormalities dysregulate the emotional brain in schizophrenia? *Prog. Neurobiol.* 77, 283–298. <https://doi.org/10.1016/j.pneurobio.2005.11.005>.
- Allen, H.N., Bobnar, H.J., Kolber, B.J., 2021. Left and right hemispheric lateralization of the amygdala in pain HHS public access. *Prog. Neurobiol.* 196, 101891 <https://doi.org/10.1016/j.pneurobio.2020.101891>.
- Alper, J., Seifert, A.C., Verma, G., Huang, K.-H., Jacob, Y., Al Qadi, A., Rutland, J.W., Patel, S., Bederson, J., Shrivastava, R.K., et al., 2021. Leveraging high-resolution 7-tesla MRI to derive quantitative metrics for the trigeminal nerve and subnuclei of limbic structures in trigeminal neuralgia. *J. Headache Pain.* 22, 1–9.
- Amano, T., Duvarci, S., Popa, D., Paré, D., 2011. The fear circuit revisited: contributions of the basal amygdala nuclei to conditioned fear. *J. Neurosci.* 31, 15481–15489. <https://doi.org/10.1523/JNEUROSCI.3410-11.2011>.
- Athey, T.L., Ceritoglu, C., Tward, D.J., Kuttan, K.S., DePaulo, J.R., Glazer, K., Goes, F.S., Kelsoe, J.R., Mondimore, F., Nievergelt, C.M., et al., 2021. A 7 tesla amygdala-hippocampal shape analysis of lithium response in bipolar disorder. *Front Psychiatry* 12, 614010.
- Batsikadze, G., Diekmann, N., Ernst, T.M., Klein, M., Maderwald, S., Deuschl, C., Merz, C. J., Cheng, S., Quick, H.H., Timmann, D., 2022. The cerebellum contributes to context-effects during fear extinction learning: a 7T fMRI study. *Neuroimage* 253. <https://doi.org/10.1016/j.neuroimage.2022.119080>.
- Benaroch, E.E., 2015. The amygdala: functional organization and involvement in neurologic disorders. *Neurology* 84, 313–324. <https://doi.org/10.1212/WNL.0000000000001171>.
- Besteher, B., Gaser, C., Nenadić, I., 2020. Brain structure and subclinical symptoms: a dimensional perspective of psychopathology in the depression and anxiety spectrum. *Neuropsychobiology* 79, 270–283. <https://doi.org/10.1159/000501024>.
- Brand, M., Grabenhorst, F., Starcke, K., Vandekerckhove, M.M.P., Markowitsch, H.J., 2007. Role of the amygdala in decisions under ambiguity and decisions under risk: evidence from patients with Urbach-Wiethe disease. *Neuropsychologia* 45, 1305–1317 <https://doi.org/10.1016/j.neuropsychologia.2006.09.021>.
- Brand, M., Snagowski, J., Laier, C., Maderwald, S., 2016. Ventral striatum activity when watching preferred pornographic pictures is correlated with symptoms of internet pornography addiction. *Neuroimage* 129, 224–232. <https://doi.org/10.1016/j.neuroimage.2016.01.033>.
- Brown, S.S.G., Rutland, J.W., Verma, G., Feldman, R.E., Alper, J., Schneider, M., Delman, B.N., Murrough, J.M., Balchandani, P., 2019. Structural MRI at 7T reveals amygdala nuclei and hippocampal subfield volumetric association with Major Depressive Disorder symptom severity, 2019 9 Sci. Rep. 1 (9), 1–10. <https://doi.org/10.1038/s41598-019-46687-7>.
- Brown, S.S.G., Rutland, J.W., Verma, G., Feldman, R.E., Schneider, M., Delman, B.N., Murrough, J.M., Balchandani, P., 2020. Ultra-high-resolution imaging of amygdala subnuclei structural connectivity in major depressive disorder. *Biol. Psychiatry Cogn. Neurosci. Neuroimaging* 5, 184–193. <https://doi.org/10.1016/j.bpsc.2019.07.010>.
- Busler, J.N., Yanes, J.A., Bird, R.T., Reid, M.A., Robinson, J.L., 2019. Differential functional patterns of the human posterior cingulate cortex during activation and deactivation: a meta-analytic connectivity model. *Exp. Brain Res.* 237, 2367–2385.
- Cattarinussi, G., Delvecchio, G., Maggioni, E., Bressi, C., Brambilla, P., 2021. Ultra-high field imaging in Major Depressive Disorder: a review of structural and functional studies. *J. Affect Disord.* 290, 65–73. <https://doi.org/10.1016/j.jad.2021.04.056>.
- Chen, J., Huang, X., Lu, C., Liu, T., Dai, Y., Yao, Z., Chen, Y., 2020. Graph analysis of DTI-based connectome: decreased local efficiency of subcortical regions in PE patients with high sympathetic activity. *Andrology* 8, 400–406. <https://doi.org/10.1111/ANDR.12701>.
- Cheng, D.T., Knight, D.C., Smith, C.N., Stein, E.A., Helmstetter, F.J., 2003. Functional MRI of human amygdala activity during Pavlovian fear conditioning: stimulus processing versus response expression. *Behav. Neurosci.* 117, 3–10. <https://doi.org/10.1037/0735-7044.117.1.3>.
- Cui, D., Guo, Y., Cao, W., Gao, W., Qiu, J., Su, L., Jiao, Q., Lu, G., Haller, S., Serafini, G., Martino Hospital, S., Luke Norman, I., 2020. Correlation between decreased amygdala subnuclei volumes and impaired cognitive functions in pediatric bipolar disorder (Article), 11, 1. <https://doi.org/10.3389/fpsy.2020.00612>.
- deCampo, D.M., Fudge, J.L., 2012. Where and what is the paralaminar nucleus? A review on a unique and frequently overlooked area of the primate amygdala. *Neurosci. Biobehav. Rev.* 36, 520–535. <https://doi.org/10.1016/j.neubiorev.2011.08.007>.
- Derix, J., Yang, S., Lüsebrink, F., Fiederer, L.D.J., Schulze-Bonhage, A., Aertsen, A., Speck, O., Ball, T., 2014. Visualization of the amygdalo-hippocampal border and its structural variability by 7T and 3T magnetic resonance imaging. *Hum. Brain Mapp.* 35, 4316–4329.
- Ding, S.L., Royall, J.J., Sunkin, S.M., Ng, L., Facer, B.A.C., Lesnar, P., Guillozet-Bongaarts, A., McMurray, B., Szafer, A., Dolbeare, T.A., Stevens, A., Tirrell, L., Benner, T., Caldejon, S., Dalley, R.A., Dee, N., Lau, C., Nyhus, J., Reding, M., Riley, Z.L., Sandman, D., Shen, E., van der Kouwe, A., Varjabedian, A., Write, M., Zollei, L., Dang, C., Knowles, J.A., Koch, C., Phillips, J.W., Sestan, N., Wahnoutka, P., Zielke, H.R., Hohmann, J.G., Jones, A.R., Bernard, A., Hawrylycz, M.J., Hof, P.R., Fischl, B., Lein, E.S., 2016. Comprehensive cellular-resolution atlas of the adult human brain. *J. Comp. Neurol.* 524, 3127–3481. <https://doi.org/10.1002/CNE.24080>.
- Evans, K.C., Wright, C.I., Wedig, M.M., Gold, A.L., Pollack, M.H., Rauch, S.L., 2008. A functional MRI study of amygdala responses to angry schematic faces in social anxiety disorder. *Depress Anxiety* 25, 496–505. <https://doi.org/10.1002/da.20347>.
- Fanselow, M.S., Ledoux, J.E., 1999. Why we think plasticity underlying viewpoint pavlovian fear conditioning occurs in the basolateral amygdala. *Neuron* 23, 229–232.
- Faull, O.K., Jenkinson, M., Clare, S., Pattinson, K.T.S., 2015. Functional subdivision of the human periaqueductal grey in respiratory control using 7 tesla fMRI. *Neuroimage* 113, 356–364. <https://doi.org/10.1016/j.neuroimage.2015.02.026>.
- Feinstein, J.S., Adolphs, R., Damasio, A., Tranel, D., 2011. The human amygdala and the induction and experience of fear. *Curr. Biol.* 21, 34–38. <https://doi.org/10.1016/j.cub.2010.11.042/ATTACHMENT/24736DF4-F708-4767-8C58-A4186B32B51D/MMCI.PDF>.
- Fischi-Gomez, E., Bonnier, G., Ward, N., Granziera, C., Hadjikhani, N., 2021. Ultrahigh field in vivo characterization of microstructural abnormalities in the orbitofrontal cortex and amygdala in autism. *Eur. J. Neurosci.* 54, 6229–6236.
- Fudge, J.L., Tucker, T., 2009. Amygdala projections to central amygdaloid nucleus subdivisions and transition zones in the primate. *Neuroscience* 159, 819–841. <https://doi.org/10.1016/j.neuroscience.2009.01.013>.
- Garrett, A., Chang, K., 2008. The role of the amygdala in bipolar disorder development. *Dev. Psychopathol.* 20, 1285–1296.
- Geissberger, N., Tik, M., Sladky, R., Woletz, M., Schuler, A.-L., Willinger, D., Windischberger, C., 2020. Reproducibility of amygdala activation in facial emotion processing at 7T. *Neuroimage* 211, 116585.
- Gläscher, J., Adolphs, R., 2003. Processing of the Arousal of Subliminal and Supraliminal Emotional Stimuli by the Human Amygdala.
- Glasser, M.F., Smith, S.M., Marcus, D.S., Andersson, J.L.R., Auerbach, E.J., Behrens, T.E. J., Coalson, T.S., Harms, M.P., Jenkinson, M., Moeller, S., Robinson, E.C., Sotiropoulos, S.N., Xu, J., Yacoub, E., Ugurbil, K., van Essen, D.C., 2016. The human connectome project's neuroimaging approach. *Nat. Neurosci.* 19, 1175. <https://doi.org/10.1038/NN.4361>.
- Goossens, L., Kukulja, J., Onur, O.A., Fink, G.R., Maier, W., Griez, E., Schruers, K., Hurlmann, R., 2009. Selective processing of social stimuli in the superficial amygdala. *Hum. Brain Mapp.* 30, 3332–3338. <https://doi.org/10.1002/HBM.20755>.
- Gorka, A.X., Torrisi, S., Shackman, A.J., Grillon, C., Ernst, M., 2018. Intrinsic functional connectivity of the central nucleus of the amygdala and bed nucleus of the stria terminalis. *Neuroimage* 168, 392–402.
- Goto, F., Kiyama, Y., Ogawa, I., Okuno, H., Ichise, T., Ichise, H., Anai, M., Kodama, T., Yoshida, N., Bito, H., Manabe, T., 2022. Gastrin-releasing peptide regulates fear learning under stressed conditions via activation of the amygdalostratial transition area, 2021 27 Mol. Psychiatry 3 (27), 1694–1703. <https://doi.org/10.1038/s41380-021-01408-3>.
- Grant, M.M., Wood, K., Sreenivasan, K., Wheelock, M., White, D., Thomas, J., Knight, D. C., Deshpande, G., 2015. Influence of early life stress on intra- and extra-amygdaloid causal connectivity. *Neuropsychopharmacology* 40, 1782. <https://doi.org/10.1038/NPP.2015.28>.
- Gryglewski, G., Baldinger-Melich, P., Seiger, R., Godbersen, G.M., Michenthaler, P., Klöbl, M., Spurny, B., Kautzky, A., Vanicek, T., Kasper, S., Frey, R., Lanzenberger, R., 2019. Structural changes in amygdala nuclei, hippocampal subfields and cortical thickness following electroconvulsive therapy in treatment-resistant depression: longitudinal analysis. *Br. J. Psychiatry* 214, 159–167. <https://doi.org/10.1192/bjp.2018.224>.
- Güntürkün, O., 2019. Biologische Psychologie. Hogrefe Verlag.
- Hagihara, K.M., Bukalo, O., Zeller, M., Aksoy-Aksel, A., Karalis, N., Limoges, A., Rigg, T., Campbell, T., Mendez, A., Weinholtz, C., Mahn, M., Zweifel, L.S., Palminter, R.D.,

- Ehrlich, I., Lüthi, A., Holmes, A., 2021. Intercalated amygdala clusters orchestrate a switch in fear state, 2021 594 *Nature* 7863 (594), 403–407. <https://doi.org/10.1038/s41586-021-03593-1>.
- Hamilton, J.P., Siemer, M., Gotlib, I.H., 2008. Amygdala volume in major depressive disorder: a meta-analysis of magnetic resonance imaging studies, 2008 13 *Mol. Psychiatry* 11 (13), 993–1000. <https://doi.org/10.1038/mp.2008.57>.
- Hrybowski, S., Aghamohammadi-Sereshtki, A., Madan, C.R., Shafer, A.T., Baron, C.A., Seres, P., Beaulieu, C., Olsen, F., Malykhin, N.V., 2016. Amygdala subnuclei response and connectivity during emotional processing. *Neuroimage* 133, 98–110. <https://doi.org/10.1016/j.neuroimage.2016.02.056>.
- Huggins, A.A., Weis, C.N., Parisi, E.A., Bennett, K.P., Miskovic, V., Larson, C.L., 2021. Neural substrates of human fear generalization: A 7T-fMRI investigation. *Neuroimage* 239, 118308.
- Iidaka, T., Matsumoto, A., Ozaki, N., Suzuki, T., Iwata, N., Yamamoto, Y., Okada, T., Sadato, N., 2006. Volume of left amygdala subregion predicted temperamental trait of harm avoidance in female young subjects. A voxel-based morphometry study. *Brain Res* 1125, 85–93. <https://doi.org/10.1016/j.brainres.2006.09.015>.
- Ince, S., Steward, T., Harrison, B.J., Jamieson, A.J., Davey, C.G., Agathos, J.A., Moffat, B.A., Glarin, R.K., Felmington, K.L., 2023. Subcortical contributions to salience network functioning during negative emotional processing. *Neuroimage* 270, 119964. <https://doi.org/10.1016/j.neuroimage.2023.119964>.
- Jacob, Y., Morris, L.S., Verma, G., Rutter, S.B., Balchandani, P., Murrough, J.W., 2022. Altered hippocampus and amygdala subregion connectome hierarchy in major depressive disorder. *Transl. Psychiatry* 12. <https://doi.org/10.1038/s41398-022-01976-0>.
- Janak, P.H., Tye, K.M., 2015. From circuits to behaviour in the amygdala. *Nature* 517, 284. <https://doi.org/10.1038/NATURE14188>.
- Kalin, N.H., Shelton, S.E., Davidson, R.J., 2004. The role of the central nucleus of the amygdala in mediating fear and anxiety in the primate. *J. Neurosci.* 24, 5506–5515.
- Kark, S.M., Birnie, M.T., Baram, T.Z., Yassa, M.A., 2021. Functional connectivity of the human paraventricular thalamic nucleus: insights from high field functional MRI. *Front Integr. Neurosci.* 15, 662293.
- Keshavarzi, S., Sullivan, R.K.P., Ianno, D.J., Sah, P., 2014. Functional properties and projections of neurons in the medial amygdala. *J. Neurosci.* 34, 8699–8715. <https://doi.org/10.1523/JNEUROSCI.1176-14.2014>.
- Keuken, M.C., Isaacs, B.R., Trampel, R., van der Zwaag, W., Forstmann, B.U., 2018. Visualizing the human subcortex using ultra-high field magnetic resonance imaging. *Brain Topogr.* 31, 513–545. <https://doi.org/10.1007/s10548-018-0638-7>.
- Klein-Flügge, M.C., Jensen, D.E.A., Takagi, Y., Priestley, L., Verhagen, L., Smith, S.M., Rushworth, M.F.S., 2022. Relationship between nuclei-specific amygdala connectivity and mental health dimensions in humans. *Nat. Hum. Behav.* 2022, 1–18. <https://doi.org/10.1038/s41562-022-01434-3>.
- Kraff, O., Fischer, A., Nagel, A.M., Mönninghoff, C., Ladd, M.E., 2015. MRI at 7 tesla and above: demonstrated and potential capabilities. *J. Magn. Reson. Imaging* 41, 13–33. <https://doi.org/10.1002/jmri.24573>.
- Kragel, P.A., Ceko, M., Theriault, J., Chen, D., Satpute, A.B., Wald, L.W., Lindquist, M.A., Barrett, L.F., Wager, T.D., 2021. A human cingulate-pulvinar-amygdala pathway encodes negative emotion. *Neuron* 109, 2404–2412.
- Kraus, C., Seiger, R., Pfabigan, D.M., Sladky, R., Tik, M., Paul, K., Woletz, M., Gryglewski, G., Vanicek, T., Komorowski, A., Kasper, S., Lamm, C., Windischberger, C., Lanzenberger, R., 2019. Hippocampal subfields in acute and remitted depression—an ultra-high field magnetic resonance imaging study. *Int. J. Neuropsychopharmacol.* 22, 513–522. <https://doi.org/10.1093/ijnp/pyz030>.
- Kreuder, A.-K., Scheele, D., Schultz, J., Hennig, J., Marsh, N., Dellert, T., Ettinger, U., Philippen, A., Babasiz, M., Herscheid, A., others, 2020. Common and dissociable effects of oxytocin and lorazepam on the neurocircuitry of fear. *Proceedings of the National Academy of Sciences* 117, 11781–11787.
- Lang, P.J., Bradley, M.M., Cuthbert, Greenwald, M., Dhman, A., Vaid, D., Hamm, A., Cook, E., Bertron, A., Petry, M., Bruner, R., Mcmanis, M., Zabaldo, D., Martinet, S., Cuthbert, S., Ray, D., Koller, K., Kolchakian, M., Hayden, S., 1997. International affective picture system (IAPS): technical manual and affective ratings. *NIMH Cent. Study Emot. Atten.* 1, 3.
- LeDoux, J.E., 1993. Emotional memory: in search of systems and synapses.
- LeDoux, J.E., 2007. The amygdala. *Current biology* 17, R868–R874.
- LeDoux, J.E., Muller, J., 1997. Emotional memory and psychopathology. *Philos. Trans. R. Soc. Lond. B Biol. Sci.* 352, 1719–1726.
- Likhtik, E., Popa, D., Apergis-Schoute, J., Fidacaro, G.A., Paré, D., 2008. Amygdala intercalated neurons are required for expression of fear extinction, 2008 454 *Nature* 7204 (454), 642–645. <https://doi.org/10.1038/nature07167>.
- Lohmann, G., Stelzer, J., Lacosse, E., Kumar, V.J., Mueller, K., Kuehn, E., Grodd, W., Scheffler, K., 2018. LISA improves statistical analysis for fMRI. *Nat. Commun.* 9. <https://doi.org/10.1038/s41467-018-06304-Z>.
- Mahon, P.B., Lee, D.S., Trinh, H., Tward, D., Miller, M.I., Younes, L., Barta, P.E., Ratnanather, J.T., 2015. Morphometry of the amygdala in schizophrenia and psychotic bipolar disorder. *Schizophrenia Res.* 164, 199–202.
- Makhalova, J., Le Troter, A., Aubert-Conil, S., Giusiano, B., McGonigal, A., Trebuchon, A., Carron, R., Villalon, S.M., Bénar, C.G., Ranjeva, J.-P., et al., 2022. Epileptogenic networks in drug-resistant epilepsy with amygdala enlargement: assessment with stereo-EEG and 7 T MRI. *Clin. Neurophysiol.* 133, 94–103.
- Markowitsch, H.J., 1998. Differential contribution of right and left amygdala to affective information processing. *Behav. Neurol.* 11, 233–244.
- McDonald, A.J., 2020. Functional neuroanatomy of the basolateral amygdala: neurons, neurotransmitters, and circuits. *Handb. Behav. Neurosci.* 26, 1–38. <https://doi.org/10.1016/B978-0-12-815134-1.00001-5>.
- McDonald, A.J., Mott, D.D., 2017. Functional neuroanatomy of amygdalohippocampal interconnections and their role in learning and memory. *J. Neurosci. Res* 95, 797. <https://doi.org/10.1002/JNR.23709>.
- Milkowski, M., Hensel, W.M., Hohol, M., 2018. Replicability or reproducibility? On the replication crisis in computational neuroscience and sharing only relevant detail. *J. Comput. Neurosci.* 45, 163–172.
- Morris, J.S., Ohman, A., Dolan, R.J., 1998. Conscious and unconscious emotional learning in the human amygdala, 1998 393 *Nature* 6684 (393), 467–470. <https://doi.org/10.1038/30976>.
- Morris, J.S., Debonis, M., Dolan, R.J., 2002. Human Amygdala Responses to Fearful Eyes. <https://doi.org/10.1006/nimg.2002.1220>.
- Murphy, J.E., Yanes, J.A., Kirby, L.A.J., Reid, M.A., Robinson, J.L., 2020. Left, right, or bilateral amygdala activation? How effects of smoothing and motion correction on ultra-high field, high-resolution functional magnetic resonance imaging (fMRI) data alter inferences. *Neurosci. Res* 150, 51–59.
- Ocklenburg, S., Peterburs, J., Mundorf, A., 2022. Hemispheric asymmetries in the amygdala: a comparative primer. *Prog. Neurobiol.*, 102283.
- Oh, B.H., Moon, H.C., Kim, A., Kim, H.J., Cheong, C.J., Park, Y.S., 2021. Prefrontal and hippocampal atrophy using 7-tesla magnetic resonance imaging in patients with Parkinson's disease. *Acta Radio. Open* 10, 2058460120988097.
- Oler, J.A., Tromp, D.P.M., Fox, A.S., Kovner, R., Davidson, R.J., Alexander, A.L., McFarlin, D.R., Birn, R.M., Berg, E., deCampo, B., Kalin, D.M., Fudge, J.L., N.H., 2016. Connectivity between the central nucleus of the amygdala and the bed nucleus of the stria terminalis in the non-human primate: neuronal tract tracing and developmental neuroimaging studies, 2016 222 *Brain Struct. Funct.* 1 (222), 21–39. <https://doi.org/10.1007/S00429-016-1198-9>.
- Orihashi, R., Mizoguchi, Y., Imamura, Y., Yamada, S., Ueno, T., Monji, A., 2020. Oxytocin and elderly MRI-based hippocampal and amygdala volume: a 7-year follow-up study. *Brain Commun.* 2. <https://doi.org/10.1093/BRAINCOMMS/FCAA081>.
- Orsini, C.A., Kim, J.H., Knapska, E., Maren, S., 2011. Hippocampal and prefrontal projections to the basal amygdala mediate contextual regulation of fear after extinction. *J. Neurosci.* 31, 17269–17277. <https://doi.org/10.1523/JNEUROSCI.4095-11.2011>.
- Pabba, M., 2013. Evolutionary development of the amygdaloid complex. *Front Neuroanat* 7, 27. <https://doi.org/10.3389/FNANA.2013.00027/BIBTEX>.
- Palomero-Gallagher, N., Amunts, K., 2021. A short review on emotion processing: a lateralized network of neuronal networks. *Brain Struct. Funct.* 1–12.
- Patel, V., Liu, C.S.J., Shiroishi, M.S., Hurth, K., Carmichael, J.D., Zada, G., Toga, A.W., 2020. Ultra-high field magnetic resonance imaging for localization of corticotropin-secreting pituitary adenomas, 2020 62 *Neuroradiology* 8 (62), 1051–1054. <https://doi.org/10.1007/S00234-020-02431-X>.
- Pedersen, W.S., Mufufuler, L.T., Larson, C.L., 2017. Disentangling the effects of novelty, valence and trait anxiety in the bed nucleus of the stria terminalis, amygdala and hippocampus with high resolution 7T fMRI. *Neuroimage* 156, 293–301.
- Pedersen, W.S., Mufufuler, L.T., Larson, C.L., 2019. A high-resolution fMRI investigation of BNST and centromedial amygdala activity as a function of affective stimulus predictability, anticipation, and duration. *Soc. Cogn. Affect Neurosci.* 14, 1167–1177.
- Phelps, E.A., LeDoux, J.E., 2005. Contributions of the amygdala to emotion processing: from animal models to human behavior. *Neuron* 48, 175–187. <https://doi.org/10.1016/j.neuron.2005.09.025>.
- Raam, T., Hong, W., 2021. Organization of neural circuits underlying social behavior: a consideration of the medial amygdala. *Curr. Opin. Neurobiol.* 68, 124–136. <https://doi.org/10.1016/j.conb.2021.02.008>.
- Rauch, S.L., Shin, L.M., Wright, C.I., 2003. Neuroimaging studies of amygdala function in anxiety disorders. *Ann. N. Y. Acad. Sci.* 985, 389–410. <https://doi.org/10.1111/J.1749-6632.2003.TB07096.X>.
- Robertson, R.V., Crawford, L.S., Meylakh, N., Macey, P.M., Macefield, V.G., Keay, K.A., Henderson, L.A., 2022. Regional hypothalamic, amygdala, and midbrain periaqueductal gray matter recruitment during acute pain in awake humans: a 7-Tesla functional magnetic resonance imaging study. *Neuroimage* 259, 119408. <https://doi.org/10.1016/j.neuroimage.2022.119408>.
- Roddy, D., Kelly, J.R., Farrell, C., Doolin, K., Roman, E., Nasa, A., Frodl, T., Harkin, A., O'Mara, S., O'Hanlon, E., O'Keane, V., 2021. Amygdala substructure volumes in Major Depressive Disorder. *Neuroimage Clin.* 31, 102781. <https://doi.org/10.1016/j.nicl.2021.102781>.
- Root, C.M., Denny, C.A., Hen, R., Axel, R., 2014. The participation of cortical amygdala in innate, odour-driven behaviour, 2014 515 *Nature* 7526 (515), 269–273. <https://doi.org/10.1038/nature13897>.
- Rubinow, M.J., Mahajan, G., May, W., Overholser, J.C., Jurjus, G.J., Dieter, L., Herbst, N., Steffens, D.C., Miguel-Hidalgo, J.J., Rajkowska, G., Stockmeier, C.A., 2016. Basolateral amygdala volume and cell numbers in major depressive disorder: a postmortem stereological study. *Brain Struct. Funct.* 221, 171–184. <https://doi.org/10.1007/S00429-014-0900-Z/FIGURES/4>.
- Sawada, M., Adolphs, R., Dlouhy, B.J., Jenison, R.L., Rhone, A.E., Kovach, C.K., Greenlee, J.D.W., Howard, M.A., Oya, H., 2022. Mapping effective connectivity of human amygdala subdivisions with intracarotid stimulation, 2022 133 *Nat. Commun.* 1 (13), 1–19. <https://doi.org/10.1038/s41467-022-32644-y>.
- Schlüter, C., Fraenz, C., Friedrich, P., Güntürkün, O., Genç, E., 2022. Neurite density imaging in amygdala nuclei reveals interindividual differences in neuroticism. *Hum. Brain Mapp.* 43, 2051–2063. <https://doi.org/10.1002/HBM.25775>.
- Sedwick, V.M., Autry, A.E., 2022. Anatomical and molecular features of the amygdalohippocampal transition area and its role in social and emotional behavior processes. *Neurosci. Biobehav. Rev.* 142, 104893. <https://doi.org/10.1016/J.NEUBIOREV.2022.104893>.

- Siemens Healthcare GmbH, 2022. MAGNETOM Terra – 7T MRT-Scanner [WWW Document]. URL <https://www.siemens-healthineers.com/de/magnetic-resonance-imaging/7t-mri-scanner/magnetom-terra> (accessed 7.27.22).
- Sladky, R., Baldinger, P., Kranz, G.S., Tröstl, J., Höfllich, A., Lanzenberger, R., Moser, E., Windischberger, C., 2013. High-resolution functional MRI of the human amygdala at 7 T. *Eur. J. Radio.* 82, 728–733. <https://doi.org/10.1016/J.EJRAD.2011.09.025>.
- Sladky, R., Geissberger, N., Pfabigan, D.M., Kraus, C., Tik, M., Woletz, M., Paul, K., Vanicek, T., Auer, B., Kranz, G.S., Lamm, C., Lanzenberger, R., Windischberger, C., 2018. Unsmoothed functional MRI of the human amygdala and bed nucleus of the stria terminalis during processing of emotional faces. *Neuroimage* 168, 383–391. <https://doi.org/10.1016/J.NEUROIMAGE.2016.12.024>.
- Sladky, R., Hahn, A., Karl, I.L., Geissberger, N., Kranz, G.S., Tik, M., Kraus, C., Pfabigan, D.M., Gartus, A., Lanzenberger, R., Lamm, C., Windischberger, C., 2022. Dynamic Causal Modeling of the Prefrontal/Amygdala Network During Processing of Emotional Faces. <https://home.liebertpub.com/brain> 12, 670–682. <https://doi.org/10.1089/BRAIN.2021.0073>.
- Thielen, J.W., Gancheva, S., Hong, D., Rohani Rankouhi, S., Chen, B., Apostolopoulou, M., Anadol-Schmitz, E., Roden, M., Norris, D.G., Tendolkar, I., 2019. Higher GABA concentration in the medial prefrontal cortex of Type 2 diabetes patients is associated with episodic memory dysfunction. *Hum. Brain Mapp.* 40, 4287–4295. <https://doi.org/10.1002/HBM.24702>.
- Tillman, R.M., Stockbridge, M.D., Nacewicz, B.M., Torrisi, S., Fox, A.S., Smith, J.F., Shackman, A.J., 2018. Intrinsic functional connectivity of the central extended amygdala. *Hum. Brain Mapp.* 39, 1291–1312. <https://doi.org/10.1002/HBM.23917>.
- Torrisi, S., Nord, C.L., Balderston, N.L., Roiser, J.P., Grillon, C., Ernst, M., 2017. Resting state connectivity of the human habenula at ultra-high field. *Neuroimage* 147, 872–879.
- Torrisi, S., Gorka, A.X., Gonzalez-Castillo, J., O'Connell, K., Balderston, N., Grillon, C., Ernst, M., 2018. Extended amygdala connectivity changes during sustained shock anticipation, 2018 8 *Transl. Psychiatry* 1 (8), 1–12. <https://doi.org/10.1038/s41398-017-0074-6>.
- Urbach, E., Wiethé, C., 1929. Lipoidosis cutis et mucosae. *Virchows Arch. Pathol. Anat. Physiol. Klin. Med* 273, 285–319.
- Weis, C.N., Huggins, A.A., Bennett, K.P., Parisi, E.A., Larson, C.L., 2019. High-resolution resting-state functional connectivity of the extended amygdala. *Brain Connect* 9, 627–637. <https://doi.org/10.1089/BRAIN.2019.0688>.
- Wen, Z., Raio, C.M., Pace-Schott, E.F., Lazar, S.W., LeDoux, J.E., Phelps, E.A., Milad, M.R., 2022. Temporally and anatomically specific contributions of the human amygdala to threat and safety learning. *Proceedings of the National Academy of Sciences* 119, e2204066119. <https://doi.org/10.1073/PNAS.2204066119>.
- Young, E.J., Williams, C.L., 2013. Differential activation of amygdala Arc expression by positive and negatively valenced emotional learning conditions. *Front Behav. Neurosci.* 7, 191.
- Yu, K., Ahrens, S., Zhang, X., Schiff, H., Ramakrishnan, C., Fenno, L., Deisseroth, K., Zhao, F., Luo, M.H., Gong, L., He, M., Zhou, P., Paninski, L., Li, B., 2017. The central amygdala controls learning in the lateral amygdala, 2017 20 *Nat. Neurosci.* 12 (20), 1680–1685. <https://doi.org/10.1038/s41593-017-0009-9>.
- Zhang, X., Cheng, H., Zuo, Z., Zhou, K., Cong, F., Wang, B., Zhuo, Y., Chen, L., Xue, R., Fan, Y., 2018. Individualized functional parcellation of the human amygdala using a semi-supervised clustering method: a 7T resting state fMRI study. *Front Neurosci.* 12, 270.
- Zuo, Z., Li, Guo, Chen, Y., Qiao, P., Zhu, J., Wang, P., Wu, F., Yu, H., Jiang, Y., Yang, J., Li, Gongjie, Jiang, R., Du, F., 2023. Atrophy in subcortical gray matter in adult patients with moyamoya disease. *Neurol. Sci.* 44, 1709. <https://doi.org/10.1007/S10072-022-06583-X>.